Received: 23 January 2023 | Accepted: 16 March 2023

DOI: 10.1111/iej.13916

INTERNATIONAL ENDODONTIC JOURNAL | WILEY

REVIEW ARTICLE

ESE position statement on root resorption

Shanon Patel[1,2] | **Gabriel Krastl**[3] | **Roland Weiger**[4] | **Paul Lambrechts**[5] | **Leo Tjäderhane**[6,7] | **Gianluca Gambarini**[8] | **Peng-Hui Teng**[1]

[1]Department of Endodontology, King's College London, London, UK

[2]Specialist Practice, London, UK

[3]Department of Conservative Dentistry, Periodontology & Center of Dental Traumatology, Universitätsklinikum Würzburg, Würzburg, Germany

[4]Department of Periodontology, Endodontology and Cariology, University Center for Dental Medicine Basel UZB, Basel, Switzerland

[5]Department of Oral Health Sciences, Endodontology, University Hospitals Leuven, KU Leuven, Leuven, Belgium

[6]Department of Oral and Maxillofacial Diseases, University of Helsinki, Helsinki, Finland

[7]University Hospital, University of Oulu, Oulu, Finland

[8]Universita degli Studi di Roma La Sapienza, Roma, Italy

Correspondence
Shanon Patel, Faculty of Dentistry, Oral & Craniofacial Sciences, King's College London, UK.
Email: shanonpatel@gmail.com

Abstract

This Position Statement on root resorption represents the consensus of an expert committee convened by the European Society of Endodontology (ESE). The statement is based on current clinical and scientific evidence as well as the expertise of the committee. The aim is to provide clinicians with authoritative information on the aetiology, histopathology, clinical presentation and recommendations for the management of root resorption. It is the intention of the committee to update this position statement at appropriate intervals as further evidence emerges.

KEYWORDS

external root resorption, internal root resorption, root resorption

INTRODUCTION

Root resorption (RR) is the loss of dental hard tissue due to odontoclastic activity (Patel, Mavridou, et al., 2018; Patel & Saberi, 2018). Injury and/or irritation of the protective, non-collagenous organic outer aspect of the root canal wall (odontoblast layer and predentine) or outer root surface (precementum and periodontal ligament) may result in internal or external root resorption, respectively. Root resorption is a consequence of odontoclast recruitment to the site of injury or irritation by the release of proinflammatory cytokines, resulting in root resorption (Wedenberg, 1987; Wedenberg & Lindskog, 1987).

Root resorption originating, inside the tooth, on the root canal wall is described as internal root resorption (IRR), while RR originating on the external root surface

Further additions, comments and consensus by ESE Executive Board members: Duncan HF, Franco V, Galler K, Jarad F, Kirkevang L-L, Rechenberg D and Whitworth J.

is described as external root resorption (ERR). In most cases, it is irreversible and typically *pathological* in nature. Depending on the type of resorption and patient symptoms, resorption may require immediate treatment or periodic monitoring (Table 1). The prevalence of various types of RR is poorly reported in the literature due to the heterogeneity of methods for its identification and quantification (Patel et al., 2022).

INTERNAL ROOT RESORPTION

Internal inflammatory and internal replacement root resorption

Aetiology

The aetiology of IRR is unclear. Several potential predisposing factors have been suggested, including traumatic dental injuries (TDI; Andreasen, 1970), and pulp inflammation as a reaction of the tissue to infection approaching the area of resorption (Gabor et al., 2012).

Pathogenesis

Internal root resorption is initiated by damage to the odontoblastic and unmineralized predentine layer, resulting in exposure of mineralized dentine to pulp tissue, the migration of odontoclasts to the site of injury and resorption of the altered root canal walls. This process may be *transient* and self-limiting, particularly during the initial phases of intra-alveolar root fracture healing and is referred to as internal surface or internal tunnel resorption (Andreasen & Andreasen, 1988). Such lesions may heal without endodontic intervention (Krastl et al., 2021).

Most IRRs are *progressive* and can be divided into two subtypes: inflammatory (infection-related) and replacement IRR. The inflammatory subtype involves the resorption of intra-radicular dentine and consists of granulation tissue only. Internal inflammatory root resorption is stimulated by bacteria from the necrotic coronal pulp and sustained by vital pulp tissue apical to the resorptive front (Wedenberg & Lindskog, 1987). The replacement subtype consists of a combination of granulation tissue and 'metaplastic' bone-like hard tissue within the resorptive defect (Patel et al., 2010).

Clinical features

Transient IRRs usually do not show clinical signs other than those related to the root fracture itself.

Both subtypes of progressive IRR share similar clinical findings and their clinical features depend on pulp status. IRR is often asymptomatic and the affected tooth responds normally to pulp sensibility tests. It may also present with the symptoms and signs of acute pulpitis and/or apical periodontitis (Patel et al., 2022).

Radiographic features

Both types of transient IRRs start at the fracture line of root-fractured teeth (Figure 1). Internal surface resorptions appear as circular radiolucent areas at the intersection of the root canal and fracture line due to a rounding of the fracture edges at the pulpal aspect of the fracture and are self-limiting. Internal tunnelling resorptions leave the canal wall intact and burrow behind the predentine layer of the walls (Andreasen & Andreasen, 1988). Despite radiologic evidence of progression of the resorption within the first year, typically signs of dystrophic calcification can be seen at the resorption site at later stages of transient IRRs.

Internal inflammatory root resorption usually presents with an oval or circular-shaped radiolucency (ballooning) of the root canal outline, whereas internal replacement root resorption presents as an irregularly shaped radiolucency with mottled or cloudy appearance with a (partially) unclear outline (Figure 1). IRR can be seen at any position in the root.

Internal root resorption and external cervical resorption (ECR) often show similar radiographic features in conventional radiographs and can be confused with each other (Gulabivala & Searson, 1995; Patel et al., 2009). Cone beam computed tomography (CBCT) helps to investigate the exact nature of IRR, to distinguish IRR from ECR and to detect perforation of root canal wall by the IRR (Bhuva et al., 2011; Lima et al., 2016; Patel et al., 2022). CBCT is recommended to aid in the diagnosis and treatment planning of IRR (American Association of Endodontists/American Academy of Oral & Maxillofacial Radiology, 2015; European Society of Endodontology, 2019).

Treatment

Transient IRRs require annual clinical (pulp sensibility testing, etc.) and radiographic (periapical radiographs and/or CBCT) monitoring to ensure early detection of possible complications. The treatment aims for IRR are to disinfect the root canal system and eliminate vital apical pulp tissue, which is sustaining the IRR. The treatment options include root canal treatment (RCT) with(out) internal repair of any perforation, RCT with surgical repair of any perforation and tooth extraction (Table 1). There

TABLE 1 Summary of key recommendations for the management of root resorption (RR).

Key: Green-treatment option, Blue-Referral guidance, red-prognosis

Internal root resorption (IRR)
Transient Periodic review Referral should be considered if there is a doubt of diagnosis, how to manage and/or symptoms/signs of progressive IRR and/or apical periodontitis.
Progressive Root canal treatment +/- internal repair of perforation Referral to a suitably qualified clinician if there are signs of replacement IRR and/or a (possible) perforation Prognosis • Root canal treatment (RCT) without perforation: good. • RCT with perforation: fair-good depending on the site, size, degree of infection of the perforation Root canal treatment with root-end surgery or surgical repair of perforation Referral to a suitably qualified clinician is recommended. Prognosis • Root-end surgery of IRR (apical-third): good • RCT & perforation repair: fair-good, depending on site, size, degree of infection of the perforation *Extraction* Referral to an oral surgeon is recommended if the extraction is (potentially) complex.
External surface resorption (ESR)
Management of causative factors Referral to a suitably qualified clinician for management of aetiological factors, e.g. orthodontist, oral surgeon. Prognosis • Mild to moderate ESR: good • Severe ESR: poor to fair depending partly on occlusal loading
External cervical resorption (ECR)
External repair only (e.g. Patel 1-2Ad, 2Bd) Referral to a suitably qualified clinician is recommended *External repair & RCT (Patel 1-2Ap, 2Bp, 2Cp)* Referral to a suitably qualified clinician is recommended *Internal repair with RCT (Patel 2Bp, 2Cp, 2Dp, 3Cp, 3Dp)* Referral to a suitably qualified clinician is recommended *Intentional replantation (IR) (Patel 3Ad/p, 3Bd/p)* Referral to a suitably qualified clinician is recommended *Decoronation (Patel 3-4Cp, 3-4Cd, 3-4Dp, 3-4Dd)* Referral to a suitably qualified clinician is recommended, an MDT approach may be required if a prosthodontic replacement is being considered. *Periodic review (Patel 2-4Cp, Patel 2-4Cp Patel 2-4Dp, Patel 2-4Dp)* Referral to a specialist is recommended Prognosis ECR which is smaller and more accessible to treatment has a better prognosis, external repair has a better prognosis than internal repair.
Extraction Referral to an oral surgeon should considered when/if decoronation and/or reparative bone-like repair.
External inflammatory resorption (EIR)
RCT for treatable cases Referral to a suitably qualified clinician is recommended *Extraction for unsalvageable cases* Prognosis • Moderate to good depending on severity
External replacement resorption (ERR)
Adults *Annual periodic review* *Composite buildup of infra-occluded tooth* *Extraction and prosthodontic replacement* Referral to an appropriate experienced clinician may be considered (e.g. oral surgeon, prosthodontist) Prognosis • Moderate to good depending on severity
Children/adolescents *Composite build-up of infraoccluded tooth* *Decoronation* Referral to an appropriate, experienced clinician may be considere, a MDT approach is likely. *Extraction with autotransplantation/prosthesis/ orthodontic space closure* Referral to appropriate specialist(s) is recommended, a MDT approach is likely.
Transient apical breakdown (TAB)
Periodic review Referral to an appropriate, experienced clinician may be considered if endodontic intervention is considered Prognosis • Good

Note: In complex cases, referral to a suitably qualified clinician is recommended, this in part depending on the dentist's experience and skill, as well as having access to the essential armamentarium, for example magnification and calcium silicate cements. A multi-disciplinary treatment (MDT) involving a coordinated approach between relevant dental disciplines may be required. Key: Green treatment option, Blue Referral guidance, red prognosis.

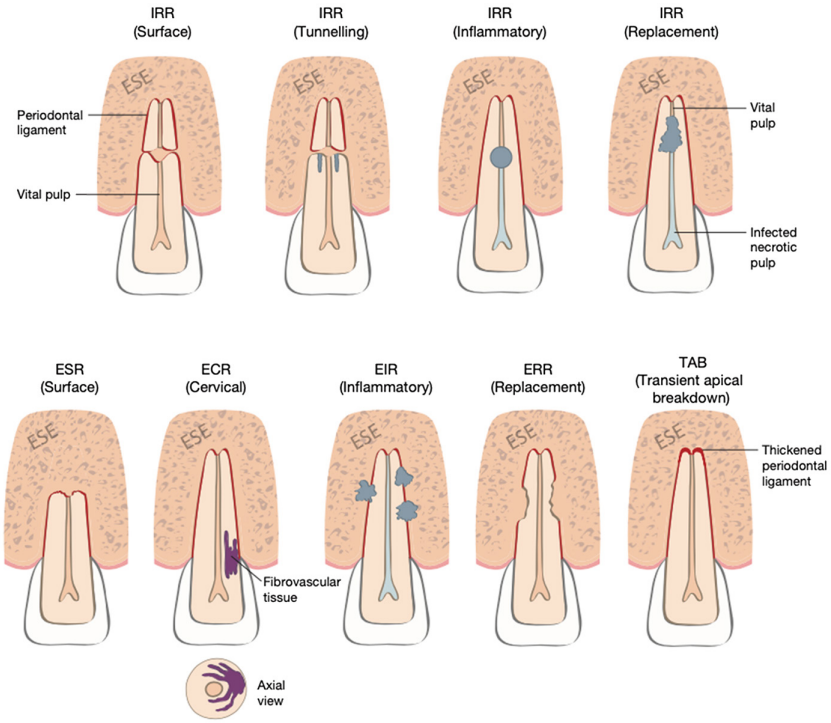

FIGURE 1 Radiographic appearance of different types of root resorption.

is a lack of strong evidence for regenerative endodontic procedures (REP) techniques for the management of IRR.

EXTERNAL ROOT RESORPTION

External surface resorption

Aetiology

External surface resorption is commonly caused by pressure exerted by trauma (luxation injuries), orthodontic treatment, adjacent impacted teeth, cysts or tumours. Minor ESR may occur without any known predisposing factor.

Pathogenesis

Pressure exerted due to traumatic dental injuries (TDI), orthodontic forces, impacted teeth, cysts or tumours may cause compression, hypoxia and/or damage to the blood vessels in the periodontal ligament (PDL), leading to damage of cementoblasts and underlying precementum on the root surface resulting in resorption by clastic cells (Colak et al., 2021; Feller et al., 2016; Kimura et al., 2003).

Clinical features

External surface resorption is usually asymptomatic with no signs of endodontic disease, and affected teeth usually respond normally to pulp sensibility tests.

Radiographic features

There is no 'classic' radiographic appearance. ESR may present as asymmetrical loss of the external root surface adjacent to the source of pressure (impacted tooth, cyst or tumour). Minor ESR may be barely detectable on a radiograph, and a perforation of root canal may be observed in advanced ESR. Flattening or blunting of the root apices may be observed in orthodontically induced ESR (Figure 1). The affected teeth may be relatively shorter than neighbouring teeth that are not subjected to high orthodontic forces. Active and stable (repaired) ESR can be distinguished by the disappearance and reestablishment of the PDL space and lamina dura, respectively. Compared with conventional radiographs, CBCT can increase the detection and improve the accuracy of assessing the extent and nature of ESR (Matzen et al., 2017; Sondeijker et al., 2020).

Treatment

The treatment objective for ESR is to manage the excessive pressure that is causing root resorption (Table 1).

External cervical resorption

Aetiology

The aetiology of ECR is poorly understood. Orthodontic treatment and a history of TDI are the most commonly

associated factors, though hypoxia has recently been proposed as a contributory factor (Heithersay, 1999; Mavridou et al., 2017, 2019). To date, all the suggested aetiological factors are considered predisposing or associated factors rather than causative (Patel et al., 2022).

Pathogenesis

The pathogenesis of ECR is complex and not fully understood. ECR is initiated by the destruction of the cementum, which allows interaction between clastic cells of the periodontium and dentine (Lindskog & Hammarström, 1980). Pathogenesis involves a three-stage process, with initiation, resorptive and reparative phases (Mavridou, Hauben, et al., 2016). In the early stages, the pulp space is protected from the resorption front by the pericanalar resorption-resistant sheet (PRRS) and the pulp tissue is vital (Mavridou, Hauben, et al., 2016). ECR only progresses into the pulp space in advanced stages. Resorption and reparative appositions can occur simultaneously in different areas in the advanced stages of ECR.

Clinical features

The clinical presentations vary depending on the location, severity and nature of ECR (European Society of Endodontology, 2018; Patel, Mavridou, et al., 2018). Early ECR is often asymptomatic and presents as an incidental finding in clinical and/or radiographic examination. Advanced ECR may present with clinical signs and/or symptoms of gingivitis, pulpitis and periapical periodontitis (Frank & Torabinejad, 1998; Patel et al., 2009).

Occasionally, the vascularized granulation tissue within the resorptive defect may manifest itself as a 'pink spot' in the cervical region of the tooth crown if the ECR lesions are on the labial/buccal or lingual/palatal surface (Heithersay, 2004). Profuse bleeding and hard and/or scratchy tactile sensation upon probing are among the other clinical findings of cavitated ECR (Liang et al., 2003; Patel et al., 2022).

Radiographic features

External cervical resorption does not have a 'classic' radiographic appearance; it may present as a radiolucency (resorptive phase) or may have a mottled appearance in moderate or advanced stages (reparative phase) (Gunst et al., 2013). The border of ECR lesions may be well-defined or have a ragged, irregular appearance (Patel et al., 2022; Patel, Mavridou, et al., 2018).

The root canal outline and PRRS should be traceable from the periapical radiograph as long as the resorption has not perforated the root canal wall (Figure 1). Parallax imaging techniques can be used to differentiate ECR from IRR and to determine the location of ECR (Durack & Patel, 2016).

The Heithersay classification is used to assess the extent of ECR based on two-dimensional radiographic findings (Heithersay, 1999) and is classified I-IV according to the coronal-apical extent of the lesion. The limitations of conventional periapical radiographs often result in an underestimation of the true extent and nature of ECR (Gunst et al., 2013; Patel, Mavridou, et al., 2018; Vaz de Souza et al., 2017).

Cone beam computed tomography improves the diagnosis and/or management of ECR by providing essential three-dimensional information about the nature and extent of the lesions, the degree of circumferential spread and proximity to the root canal (Figure 2) (Mavridou, Pyka, et al., 2016; Patel et al., 2016). The European Society of Endodontology Position Statements on CBCT and ECR recommend taking a CBCT to aid the diagnosis and management of ECR lesions (European Society of Endodontology, 2018, 2019). The Patel classification is a three-dimensional assessment of ECR based on periapical radiographs and CBCT (Figure 3) (Patel, Foschi, Mannocci, et al., 2018). The classification is anticipated to allow the objective assessment of the treatment outcome and prognostic factors in relation to the three-dimensional nature of ECR.

External cervical resorption lesions may present in multiple teeth, however, the prevalence of multiple lesions is unknown (von Arx et al., 2009).

Treatment

The aims of treatment are to excavate the resorptive tissue, restore the resorptive defect and monitor the affected tooth for recurrence (Patel, Foschi, Condon, et al., 2018; Patel, Mavridou, et al., 2018). The management of ECR depends on the nature, extent, size of portal of entry and accessibility of the lesions (Asgary et al., 2019; Irinakis, 2018; Mavridou et al., 2022; Plotino et al., 2021) (Table 1).

Prognostic factors which reduce the survival rate of teeth with ECR include posterior teeth (Irinakis, 2018) and greater extent of ECR lesions (Heithersay, 2004; Irinakis, 2018; Mavridou et al., 2022). The management options are still experimental and the outcome is often short to medium term (Beertsen et al., 2001; Reddy Kesary et al., 2014; Yu et al., 2011). For this reason, fixed/removable prosthodontic treatment options should be considered and discussed with the patient before treating the ECR.

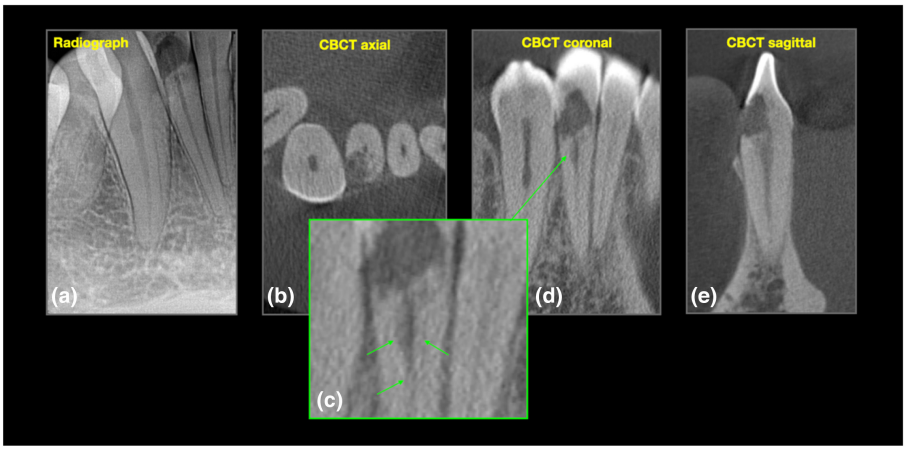

FIGURE 2 External cervical resorption (ECR; Patel 2Bp). (a) Radiograph reveals a well-defined radiolucency (resorptive/destructive phase) in the coronal aspect of the tooth, (b–e) Cone beam computed tomography reveals the ECR spreads (b) up to 180° around the tooth, (c–e) extends into the coronal-third of the root, as highlighted by the green arrows.

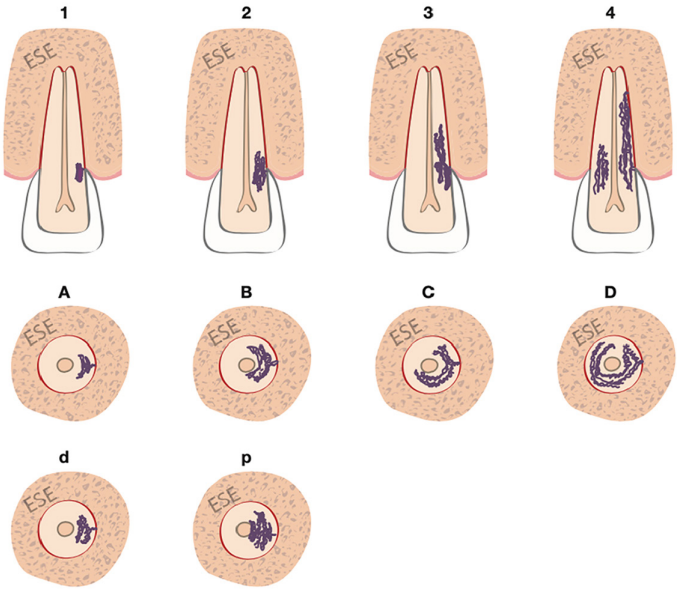

Height	Circumferential spread	Proximity to the root canal
1: At cemento-enamel junction level or coronal to the bone crest (supracrestal)	**A**: ≤90°	**d**: Confined to dentine
2: Extends into coronal third of the root and apical to the bone crest (subcrestal)	**B**: >90° to ≤180°	**p**: Probable/actual pulpal involvement
3: Extends into mid-third of the root	**C**: >180° to ≤270°	
4: Extends into apical third of the root	**D**:>270°	

FIGURE 3 The Patel classification of external cervical resorption (ECR) describes the nature (i.e. height, degree of circumferential spread and proximity to the root canal) of ECR in three dimensions and is based on PA and cone beam computed tomography assessment. With multi-root teeth, the sum total spread of ECR in an axial plane in the CEJ region ± numbers roots affected will determine circumferential spread.

External inflammatory (infection-related) resorption

Aetiology and prevalence

Rapid external inflammatory (infection-related) resorption (EIR) is initiated by a combination of damage to the protective precementum layer on the external root surface and root canal microbiome from the infected necrotic pulp (Krastl et al., 2021). It is more commonly associated with severe luxation injuries, mainly intrusion and avulsion.

External inflammatory (infection-related) resorption also occurs in the majority of infected teeth with radiographic signs of chronic apical periodontitis (Laux et al., 2000; Vier & Figueiredo, 2002), but in non-trauma cases, it is usually

restricted to the root tip, does not affect the standard endodontic treatment and will not be discussed any further here.

Pathogenesis

Damage and breach to the protective non-mineralized precementum layer must occur, clastic cells then migrate to the injury site and resorb the underlying mineralized hard tissue. The resorptive process is sustained by the diffusion of microorganisms and/or their by-products from the infected necrotic pulp (Andreasen & Hjørting-Hansen, 1966b).

Clinical features

External inflammatory (infection-related) resorption may be associated with clinical signs and symptoms of irreversible pulpitis and/or apical periodontitis, with a negative response to pulp sensibility testing. However, the majority of cases do not show clinical signs, therefore, EIR is most often detected radiographically as an incidental finding.

Radiographic features

The root may appear shorter and have a ragged appearance apically, often associated with a periapical radiolucency (Figure 1). Rapid EIR due to moderate or severe TDI usually presents with a peri-radicular ragged, crater-shaped radiolucency on the root surface and the adjacent bone (Andreasen & Hjørting-Hansen, 1966a, 1966b). Loss of lamina dura may also be observed. Perforation into the root canal may be seen in advanced EIR.

Prior to potential management, a CBCT is desirable to assess the nature of EIR and root canal perforation which could be easily missed by conventional radiographs (Durack et al., 2011).

Treatment

The treatment aim for EIR is the elimination of pulp space infection. Treatment options include RCT for treatable cases (Krastl et al., 2021), and extraction for unsalvageable cases (Table 1).

After successful root canal disinfection, periodontal healing may occur under ideal conditions, but external replacement resorption (ankylosis) is likely to develop after extensive infection-related root resorption.

There is insufficient evidence to support REP in routine clinical practice.

External replacement resorption

Aetiology

External replacement resorption is commonly associated with severe TDI and can be observed following avulsion and intrusive luxation injuries (Soares et al., 2015; Souza et al., 2018).

Pathogenesis

The damaged PDL cells may be torn, crushed and/or degenerate, resulting in their necrosis. The necrosed PDL cells (together with the damaged cementum and dentine) are then resorbed by osteoclasts and ultimately replaced with alveolar bone generated by osteoblasts (Andersson et al., 1984). Total mineralization of PDL is a common finding in ERR (Andreasen, 1980).

Clinical features

External replacement resorption may present with a lack of physiological mobility and a high-pitched or metallic sound on percussion (Andersson et al., 1984). The affected tooth may become infra-occluded if the dentition is still developing.

Pulp sensibility testing may be normal; however, ERR is typically seen in root canal-treated teeth after severe luxation injuries where timely and adequate endodontic treatment prevented the development of infection-related EIR.

Radiographic features

The absence of PDL space in the affected tooth and an irregular or 'moth-eaten' appearance are common findings (Figure 1; Andreasen & Hjørting-Hansen, 1966a). Conventional radiography may underestimate the presence and the extent of ERR, especially if the resorption is located on the buccal or palatal surface. CBCT can overcome this limitation and may be indicated to assess the true nature and extent of the ERR and the positively impact treatment planning (Durack & Patel, 2016).

Treatment

Treatment is influenced by the nature of ERR, the growth status of the patient and often involves a multi-disciplinary approach (Table 1).

Transient apical breakdown

Aetiology

Transient apical breakdown (TAB) is the transient expansion of the apical PDL in healthy teeth with fully developed roots with closed or half-closed apices associated with a recent history of TDI. It is associated with moderate TDI (extrusion and lateral luxation), occurs infrequently following mild TDI (concussion and subluxation) and is usually absent following severe TDI (intrusive luxation). In less than one-third of the cases, TAB is associated with apical ESR (Andreasen, 1986).

Pathogenesis

It has been speculated that TAB is a repair process following moderate TDI where the injured tissue is removed and replaced with normal tissue after some time.

Clinical features

Transient apical breakdown may present with mild tooth discolouration and delayed or no response to pulp sensibility testing which normally resolves within a year (Andreasen, 1986; Boyd, 1995). Pulp canal obliteration (PCO) and associated discolouration (yellow) can occur following the resolution of TAB and can cause delayed or no response to sensibility testing.

Radiographic features

Widening of PDL space and blurry appearance or loss of apical lamina dura is the pathognomonic features of TAB. The radiographic appearance may return to a normal state within a year (Andreasen, 1986; Cohenca et al., 2003). External surface resorption (ESR) and PCO are consistent findings following the resolution of the early transient radiographic changes (Andreasen, 1986).

Treatment

The management of TAB depends on the risk of pulp necrosis (Patel et al., 2022; Table 1). More research into the pathogenesis, and clinical and radiographic findings of TAB may help us to diagnose and to formulate effective treatment plans for TAB.

CONCLUSION

It is important for the clinician to appreciate the different forms of resorption that can affect teeth in order to recognize and differentiate between them. For this, it is a prerequisite to know the tissues involved, to understand their pathology and the role of infection in the context. A systematic clinical and radiographic examination is paramount to ensure the appropriate management of RR.

Increasingly, CBCT is being used to confirm the diagnosis and/or aid management. The use of CBCT must be justified in each individual case based on the principle of as low as reasonably achievable (ALARA).

Robust clinical research is required to gain a deeper knowledge of the aetiology, pathogenesis and management of RR.

AUTHOR CONTRIBUTIONS

S Patel: conceptualization, methodology, visualization, resources, writing—original draft, writing—review and editing, project administration. G Krastl, R Weiger, P Lambrechts, L Tjaderhane and P-H Teng: writing, resources, review and editing. G Gambarini, writing—review and editing. Further additions, comments and consensus by ESE Executive Board members: Duncan HF, Franco V, Galler K, Jarad F, Kirkevang L-L, Rechenberg D and Whitworth J.

CONFLICT OF INTEREST STATEMENT

The authors deny any conflict of interest.

DATA AVAILABILITY STATEMENT

Data sharing not applicable to this article as no datasets were generated or analysed during the current study.

ETHICAL APPROVAL

Ethical approval was not sought for this review paper as there was no patient data used.

ORCID

Shanon Patel https://orcid.org/0000-0003-0614-6951
Gabriel Krastl https://orcid.org/0000-0002-9402-8121

REFERENCES

American Association of Endodontists/American Academy of Oral & Maxillofacial Radiology. (2015) AAE and AAOMR joint position statement: use of cone beam computed tomography in endodontics 2015 update. *Oral Surgery, Oral Medicine, Oral Pathology, Oral Radiology*, 120, 508–512.

Andersson, L., Blomlöf, L., Lindskog, S., Feiglin, B. & Hammarström, L. (1984) Tooth ankylosis: clinical,

radiographic and histological assessments. *International Journal of Oral Surgery*, 13, 423–431.

Andreasen, F.M. (1986) Transient apical breakdown and its relation to color and sensibility changes after luxation injuries to teeth. *Dental Traumatology*, 2, 9–19.

Andreasen, F.M. & Andreasen, J.O. (1988) Resorption and mineralization processes following root fracture of permanent incisors. *Endodontics & Dental Traumatology*, 4, 202–214.

Andreasen, J.O. (1970) Luxation of permanent teeth due to trauma. A clinical and radiographic follow-up study of 189 injured teeth. *Scandinavian Journal of Dental Research*, 78, 273–286.

Andreasen, J.O. (1980) Analysis of pathogenesis and topography of replacement root resorption (ankylosis) after replantation of mature permanent incisors in monkeys. *Swedish Dental Journal*, 4, 231–240.

Andreasen, J.O. & Hjørting-Hansen, E. (1966a) Replantation of teeth. I. Radiographic and clinical study of 110 human teeth replanted after accidental loss. *Acta Odontologica Scandinavica*, 24, 263–286.

Andreasen, J.O. & Hjørting-Hansen, E. (1966b) Replantation of teeth. II. Histological study of 22 replanted anterior teeth in humans. *Acta Odontologica Scandinavica*, 24, 287–306.

Asgary, S., Nourzadeh, M., Verma, P., Hicks, M.L. & Nosrat, A. (2019) Vital pulp therapy as a conservative approach for Management of Invasive Cervical Root Resorption: a case series. *Journal of Endodontics*, 45, 1161–1167.

Beertsen, W., Piscaer, M., van Winkelhoff, A.J. & Everts, V. (2001) Generalized cervical root resorption associated with periodontal disease. *Journal of Clinical Periodontology*, 28, 1067–1073.

Bhuva, B., Barnes, J.J. & Patel, S. (2011) The use of limited cone beam computed tomography in the diagnosis and management of a case of perforating internal root resorption. *International Endodontic Journal*, 44, 777–786.

Boyd, K.S. (1995) Transient apical breakdown following subluxation injury: a case report. *Endodontics & Dental Traumatology*, 11, 37–40.

Cohenca, N., Karni, S. & Rotstein, I. (2003) Transient apical breakdown following tooth luxation. *Dental Traumatology*, 19, 289–291.

Colak, C., Aras, B., Cheng, L.L., Elekdag-Turk, S., Turk, T. & Darendeliler, M.A. (2021) Effects of rapid and slow maxillary expansion on root resorption: a micro-computed tomography study. *European Journal of Orthodontics*, 43, 682–689.

Durack, C. & Patel, S. (2016) Root resorption. In: Patel, S., Harvey, S., Shemesh, H. & Durack, C. (Eds.) *Cone beam computed tomography In endodontics*, 1st edition. Berlin: Quintessence Publishing Co. Ltd, pp. 119–131.

Durack, C., Patel, S., Davies, J., Wilson, R. & Mannocci, F. (2011) Diagnostic accuracy of small volume cone beam computed tomography and intraoral periapical radiography for the detection of simulated external inflammatory root resorption. *International Endodontic Journal*, 44, 136–147.

European Society of Endodontology. (2018) European Society of Endodontology position statement: external cervical resorption. *International Endodontic Journal*, 51, 1323–1326.

European Society of Endodontology. (2019) European Society of Endodontology position statement: use of cone beam computed tomography in endodontics: European Society of Endodontology (ESE) developed by. *International Endodontic Journal*, 52, 1675–1678.

Feller, L., Khammissa, R.A.G., Thomadakis, G., Fourie, J. & Lemmer, J. (2016) Apical external root resorption and repair in orthodontic tooth movement: biological events. *BioMed Research International*, 2016, 4864195.

Frank, A.L. & Torabinejad, M. (1998) Diagnosis and treatment of extracanal invasive resorption. *Journal of Endodontics*, 24, 500–504.

Gabor, C., Tam, E., Shen, Y. & Haapasalo, M. (2012) Prevalence of internal inflammatory root resorption. *Journal of Endodontics*, 38, 24–27.

Gulabivala, K. & Searson, L.J. (1995) Clinical diagnosis of internal resorption: an exception to the rule. *International Endodontic Journal*, 28, 255–260.

Gunst, V., Mavridou, A., Huybrechts, B., Van Gorp, G., Bergmans, L. & Lambrechts, P. (2013) External cervical resorption: an analysis using cone beam and microfocus computed tomography and scanning electron microscopy. *International Endodontic Journal*, 46, 877–887.

Heithersay, G.S. (1999) Invasive cervical resorption: an analysis of potential predisposing factors. *Quintessence International*, 30, 83–95.

Heithersay, G.S. (2004) Invasive cervical resorption. *Endodontic Topics*, 7, 73–92.

Irinakis, E. (2018) *External cervical root resorption: determinants and treatment outcomes text*. Vancouver: University of British Columbia. https://open.library.ubc.ca/soa/cIRcle/collections/ubctheses/24/items/1.0373171?o=19

Kimura, R., Anan, H., Matsumoto, A., Noda, D. & Maeda, K. (2003) Dental root resorption and repair: histology and histometry during physiological drift of rat molars. *Journal of Periodontal Research*, 38, 525–532.

Krastl, G., Weiger, R., Filippi, A., van Waes, H., Ebeleseder, K., Ree, M. et al. (2021) Endodontic management of traumatized permanent teeth: a comprehensive review. *International Endodontic Journal*, 54, 1221–1245.

Laux, M., Abbott, P.V., Pajarola, G. & Nair, P.N. (2000) Apical inflammatory root resorption: a correlative radiographic and histological assessment. *International Endodontic Journal*, 33, 483–493.

Liang, H., Burkes, E.J. & Frederiksen, N.L. (2003) Multiple idiopathic cervical root resorption: systematic review and report of four cases. *Dento Maxillo Facial Radiology*, 32, 150–155.

Lima, T.F., Gamba, T.O., Zaia, A.A. & Soares, A.J. (2016) Evaluation of cone beam computed tomography and periapical radiography in the diagnosis of root resorption. *Australian Dental Journal*, 61, 425–431.

Lindskog, S. & Hammarström, L. (1980) Evidence in favor of an anti-invasion factor in cementum or periodontal membrane of human teeth. *Scandinavian Journal of Dental Research*, 88, 161–163.

Matzen, L.H., Schropp, L., Spin-Neto, R. & Wenzel, A. (2017) Radiographic signs of pathology determining removal of an impacted mandibular third molar assessed in a panoramic image or CBCT. *Dento Maxillo Facial Radiology*, 46, 20160330.

Mavridou, A.M., Bergmans, L., Barendregt, D. & Lambrechts, P. (2017) Descriptive analysis of factors associated with external cervical resorption. *Journal of Endodontics*, 43, 1602–1610.

Mavridou, A.M., Hauben, E., Wevers, M., Schepers, E., Bergmans, L. & Lambrechts, P. (2016) Understanding external cervical resorption in vital teeth. *Journal of Endodontics*, 42, 1737–1751.

Mavridou, A.M., Hilkens, P., Lambrichts, I., Hauben, E., Wevers, M., Bergmans, L. et al. (2019) Is hypoxia related to external cervical resorption? A case report. *Journal of Endodontics*, 45, 459–470.

Mavridou, A.M., Pyka, G., Kerckhofs, G., Wevers, M., Bergmans, L., Gunst, V. et al. (2016) A novel multimodular methodology to investigate external cervical tooth resorption. *International Endodontic Journal*, 49, 287–300.

Mavridou, A.M., Rubbers, E., Schryvers, A., Maes, A., Linssen, M., Barendregt, D.S. et al. (2022) A clinical approach strategy for the diagnosis, treatment and evaluation of external cervical resorption. *International Endodontic Journal*, 55, 347–373.

Patel, K., Mannocci, F. & Patel, S. (2016) The assessment and management of external cervical resorption with periapical radiographs and cone-beam computed tomography: a clinical study. *Journal of Endodontics*, 42, 1435–1440.

Patel, S., Foschi, F., Condon, R., Pimentel, T. & Bhuva, B. (2018) External cervical resorption: part 2 – management. *International Endodontic Journal*, 51, 1224–1238.

Patel, S., Foschi, F., Mannocci, F. & Patel, K. (2018) External cervical resorption: a three-dimensional classification. *International Endodontic Journal*, 51, 206–214.

Patel, S., Kanagasingam, S. & Pitt Ford, T. (2009) External cervical resorption: a review. *Journal of Endodontics*, 35, 616–625.

Patel, S., Mavridou, A.M., Lambrechts, P. & Saberi, N. (2018) External cervical resorption-part 1: histopathology, distribution and presentation. *International Endodontic Journal*, 51, 1205–1223.

Patel, S., Ricucci, D., Durak, C. & Tay, F. (2010) Internal root resorption: a review. *Journal of Endodontics*, 36, 1107–1121.

Patel, S. & Saberi, N. (2018) The ins and outs of root resorption. *British Dental Journal*, 224, 691–699.

Patel, S., Saberi, N., Pimental, T. & Teng, P.-H. (2022) Present status and future directions: root resorption. *International Endodontic Journal*, 00, 1–30.

Plotino, G., Abella Sans, F., Duggal, M.S., Grande, N.M., Krastl, G., Nagendrababu, V. et al. (2021) European Society of Endodontology position statement: surgical extrusion, intentional replantation and tooth autotransplantation. *International Endodontic Journal*, 54, 655–659.

Reddy Kesary, S., Mengji, A., Yaga, U. & Panta, P. (2014) An unusual case of idiopathic multiple invasive cervical resorption. *Journal of Indian Academy of Oral Medicine and Radiology*, 26, 229–232.

Soares, A.J., Souza, G.A., Pereira, A.C., Vargas-Neto, J., Zaia, A.A. & Silva, E.J. (2015) Frequency of root resorption following trauma to permanent teeth. *Journal of Oral Science*, 57, 73–78.

Sondeijker, C.F.W., Lamberts, A.A., Beckmann, S.H., Kuitert, R.B., van Westing, K., Persoon, S. et al. (2020) Development of a clinical practice guideline for orthodontically induced external apical root resorption. *European Journal of Orthodontics*, 42, 115–124.

Souza, B.D.M., Dutra, K.L., Kuntze, M.M., Bortoluzzi, E.A., Flores-Mir, C., Reyes-Carmona, J. et al. (2018) Incidence of root resorption after the replantation of avulsed teeth: a meta-analysis. *Journal of Endodontics*, 44, 1216–1227.

Vaz de Souza, D., Schirru, E., Mannocci, F., Foschi, F. & Patel, S. (2017) External cervical resorption: a comparison of the diagnostic efficacy using 2 different cone-beam computed tomographic units and periapical radiographs. *Journal of Endodontics*, 43, 121–125.

Vier, F.V. & Figueiredo, J.A. (2002) Prevalence of different periapical lesions associated with human teeth and their correlation with the presence and extension of apical external root resorption. *International Endodontic Journal*, 35, 710–719.

von Arx, T., Schawalder, P., Ackermann, M. & Bosshardt, D.D. (2009) Human and feline invasive cervical resorptions: the missing link? Presentation of four cases. *Journal of Endodontics*, 35, 904–913.

Wedenberg, C. (1987) Evidence for a dentin-derived inhibitor of macrophage spreading. *Scandinavian Journal of Dental Research*, 95, 381–388.

Wedenberg, C. & Lindskog, S. (1987) Evidence for a resorption inhibitor in dentin. *Scandinavian Journal of Dental Research*, 95, 205–211.

Yu, V.S.H., Messer, H.H. & Tan, K.B. (2011) Multiple idiopathic cervical resorption: case report and discussion of management options. *International Endodontic Journal*, 44, 77–85.

How to cite this article: Patel, S., Krastl, G., Weiger, R., Lambrechts, P., Tjäderhane, L., Gambarini, G. et al. (2023) ESE position statement on root resorption. *International Endodontic Journal*, 56, 792–801. Available from: https://doi.org/10.1111/iej.13916